

14th

AICT
ASIAN INTERVENTIONAL CARDIOVASCULAR THERAPEUTICS
THE OFFICIAL CONGRESS OF APSIC

How did I treat my patient?

Dr. Gary Shing-him CHEUNG

張誠謙

MBBS(HK), FHKCP (HK), FHKAM (HK)

Associate Consultant & Honorary Clinical Assistant Professor

Head of Structural Heart Intervention

Division of Cardiology, Department of Medicine & Therapeutics,
Prince of Wales Hospital, The Chinese University of Hong Kong



威爾斯親王醫院
Prince of Wales Hospital





Speaker's name : Gary Shing-Him, CHEUNG
Prince of Wales Hospiyal

I have the following potential conflicts of interest to report:


I am a physician proctor for CoreValve/Evolut (Medtronic) TAVI device

2018 © AICT Congress 2018. All rights reserved - Any reproduction even in part is prohibited.

2018 © AICT Congress 2018. All rights reserved - Any reproduction even in part is prohibited.



Baseline aortogram, then Evolut-PRO 26mm




2018 © AICT Congress 2018. All rights reserved - Any reproduction even in part is prohibited.

2018 © AICT Congress 2018. All rights reserved - Any reproduction even in part is prohibited.



Valve deployed and postdilatation by 22mm balloon




2018 © AICT Congress 2018. All rights reserved - Any reproduction even in part is prohibited.

2018 © AICT Congress 2018. All rights reserved - Any reproduction even in part is prohibited.



Post deployment aortogram and coronary angiogram




2018 © AICT Congress 2018. All rights reserved - Any reproduction even in part is prohibited.

2018 © AICT Congress 2018. All rights reserved - Any reproduction even in part is prohibited.




Repeated angiogram showed TIMI 3 flow in LAD



2018 © AICT Congress 2018. All rights reserved - Any reproduction even in part is prohibited.

2018 © AICT Congress 2018. All rights reserved - Any reproduction even in part is prohibited.

Thus the stent was not deployed



- The procedure completed uncomplicated, and wounds closed smoothly
- The patient was sent to CCU for close monitoring.

2018 © AICT Congress 2018. All rights reserved - Any reproduction even in part is prohibited.

2018 © AICT Congress 2018. All rights reserved - Any reproduction even in part is prohibited.

Acute pulmonary edema at post TAVI day 1




- Echo showed severe hypokinesia over anterior and anteroseptal wall of LV, impaired LV EF down to about 30%

2018 © AICT Congress 2018. All rights reserved - Any reproduction even in part is prohibited.

2018 © AICT Congress 2018. All rights reserved - Any reproduction even in part is prohibited.

Coronary angiogram showed left main near occlusion by native valve leaflet




2018 © AICT Congress 2018. All rights reserved - Any reproduction even in part is prohibited.

2018 © AICT Congress 2018. All rights reserved - Any reproduction even in part is prohibited.



Predilatation then stent with 3.5 x30 stent




2018 © AICT Congress 2018. All rights reserved - Any reproduction even in part is prohibited.

2018 © AICT Congress 2018. All rights reserved - Any reproduction even in part is prohibited.



**Final angiogram after
posdilatation by 4.5
balloon**



**FU Echo showed improved
regional wall motion
abnormality**



2018 © AICT Congress 2018. All rights reserved - Any reproduction even in part is prohibited.

2018 © AICT Congress 2018. All rights reserved - Any reproduction even in part is prohibited.

Learning point

- Selective angiogram post TAVI might miss ostial LM obstruction
- Read aortogram and angiogram clearly post valve deployment, especially carefully over ostial LM
- Guideliner catheter can help to pass through the strut of TAVI prosthesis

2018 © AICT Congress 2018. All rights reserved - Any reproduction even in part is prohibited.

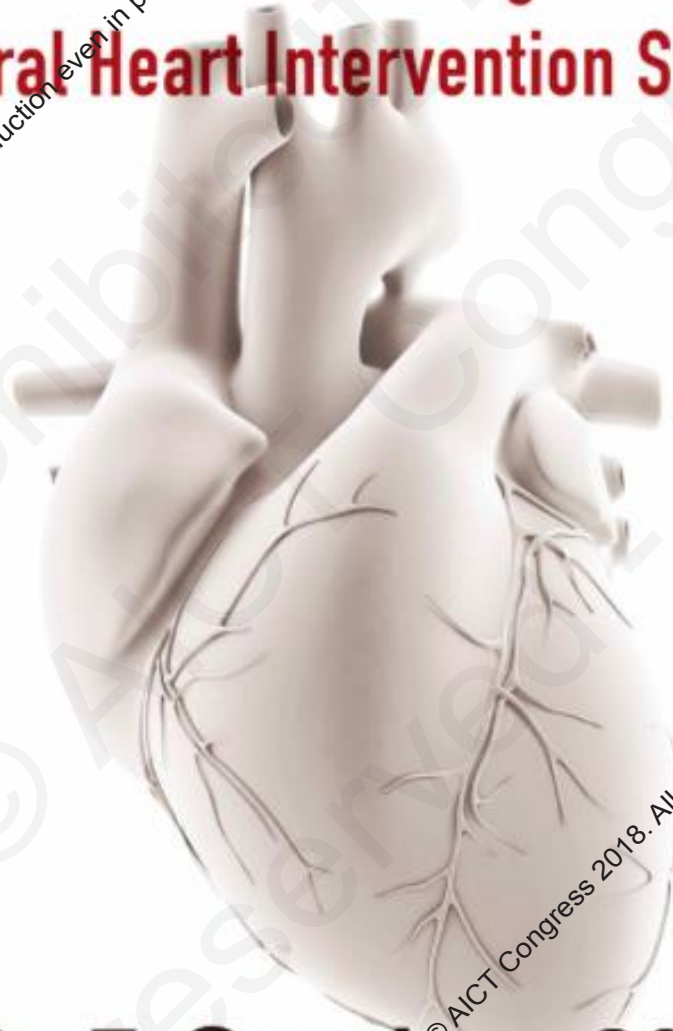
2018 © AICT Congress 2018. All rights reserved - Any reproduction even in part is prohibited.

2018

APCASH



9th Asia Pacific Congenital and Structural Heart Intervention Symposium



6 – 7 October, 2018

Hong Kong Convention & Exhibition Centre, Hong Kong

2018 © AICT Congress 2018. All rights reserved - Any reproduction even in part is prohibited.

2018 © AICT Congress 2018. All rights reserved - Any reproduction even in part is prohibited.

14th

AICT

ASIAN INTERVENTIONAL CARDIOVASCULAR THERAPEUTICS
THE OFFICIAL CONGRESS OF APSIC

7 - 9th September 2018

Hong Kong

Convention and Exhibition Centre (HKCEC)

2018 © AICT Congress 2018. All rights reserved - Any reproduction even in part is prohibited.

2018 © AICT Congress 2018. All rights reserved - Any reproduction even in part is prohibited.